PRELIMINARY EXPERIENCE AND TECHNICAL EVOLUTION ON PURE LAPAROSCOPIC HEPATECTOMY FOR ADULT LDLT

F. Rotellar, F. Pardo, A. Benito, G. Zozaya, P. Marti-Cruchaga, F. Hidalgo, L. Lopez, M. Iñarrairaegui, B. Sangro, I. Herrero.

HPB and Liver Transplant
Clinica Universidad de Navarra. - Pamplona (Spain)

Preliminary experience and technical evolution on pure laparoscopic hepatectomy for adult LDLT

- In 2013 we began to offer our liver donors the laparoscopic approach with the aim of providing them with the benefits of the minimally invasive surgery.

Preliminary experience and technical evolution on pure laparoscopic hepatectomy for adult LDLT

- In 2013 we began to offer our liver donors the laparoscopic approach with the aim of providing them with the benefits of the minimally invasive surgery.

- This presentation is focused on the surgical outcome, morbidity and **technical evolution** along this preliminary experience.

Preliminary experience and technical evolution on pure laparoscopic hepatectomy for adult LDLT

From May 2013

-7 consecutive donors: 6 RH and one LH, (all of them without the MHV).

Median age was 38 years (range 21-57); 5 were males and 2 females.

BMI 27 (21-29) kg/m^2.

Preliminary experience and technical evolution on pure laparoscopic hepatectomy for adult LDLT

From May 2013
-7 consecutive donors: 6 RH and one LH, (all of them without the MHV).

Median age was 38 years (range 21-57); 5 were males and 2 females.
BMI 27 (21-29) kg/m^2.

Preoperative study:
CT angioscan, cholangioMRI and Mevis 3D reconstruction.

Estimated graft volume was 791 (1462-376) ml.

Preliminary experience and technical evolution on pure laparoscopic hepatectomy for adult LDLT

Anatomy: All donors had single vascular and biliary elements

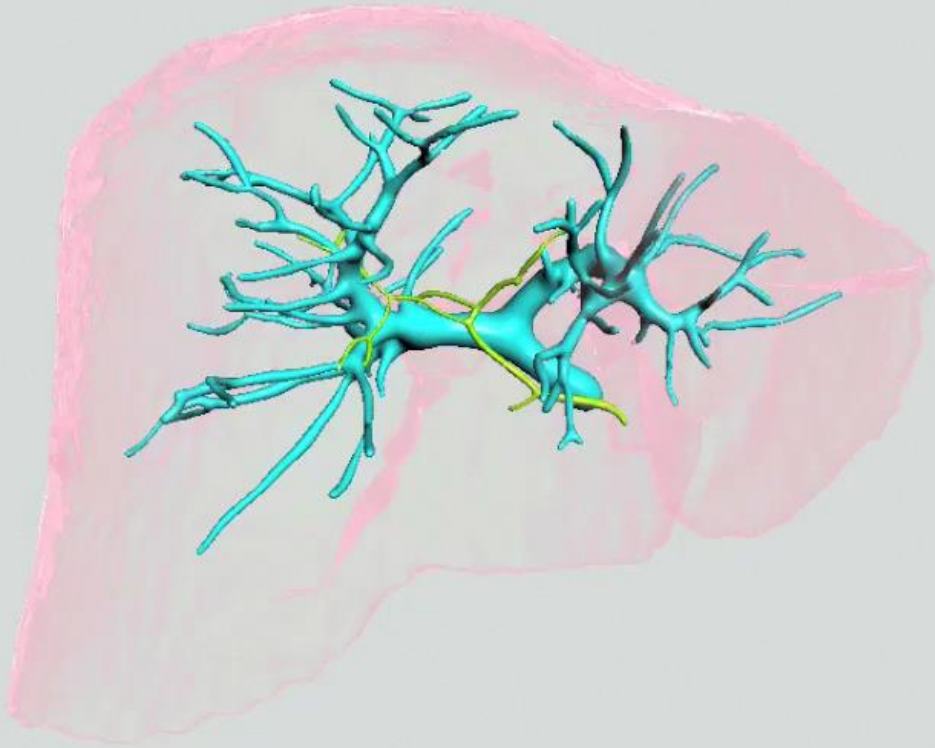

3 RH cases: two right ducts

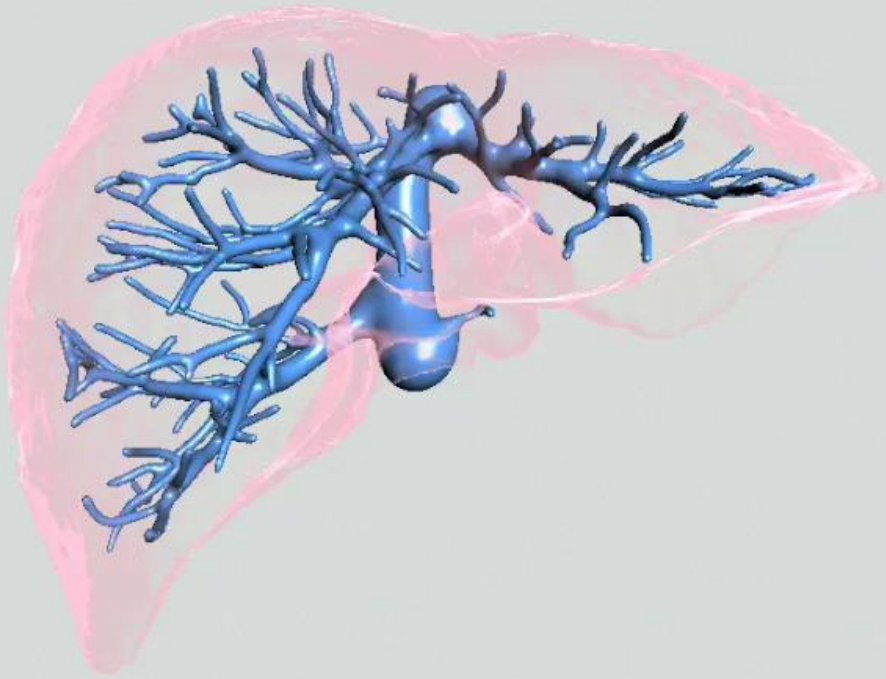

1 RH case: large IHV

Preliminary experience and technical evolution on pure laparoscopic hepatectomy for adult LDLT

American Journal of Transplantation

Totally Laparoscopic Right-Lobe Hepatectomy for Adult Living Donor Liver Transplantation: Useful Strategies to Enhance Safety

F. Rotellar[1,*], F. Pardo[1], A. Benito[2], P. Martí-Cruchaga[1], G. Zozaya[1], L. Lopez[3], F. Hidalgo[3], B. Sangro[4,5] and I. Herrero[4,5]

American Journal of Transplantation 2013; 13: 3269–3273

Preliminary experience and technical evolution on pure laparoscopic hepatectomy for adult LDLT

Technical evolution

- Right liver mobilization

- Trocar position/45º optic

- ICG fluorescence / bile duct division under direct view

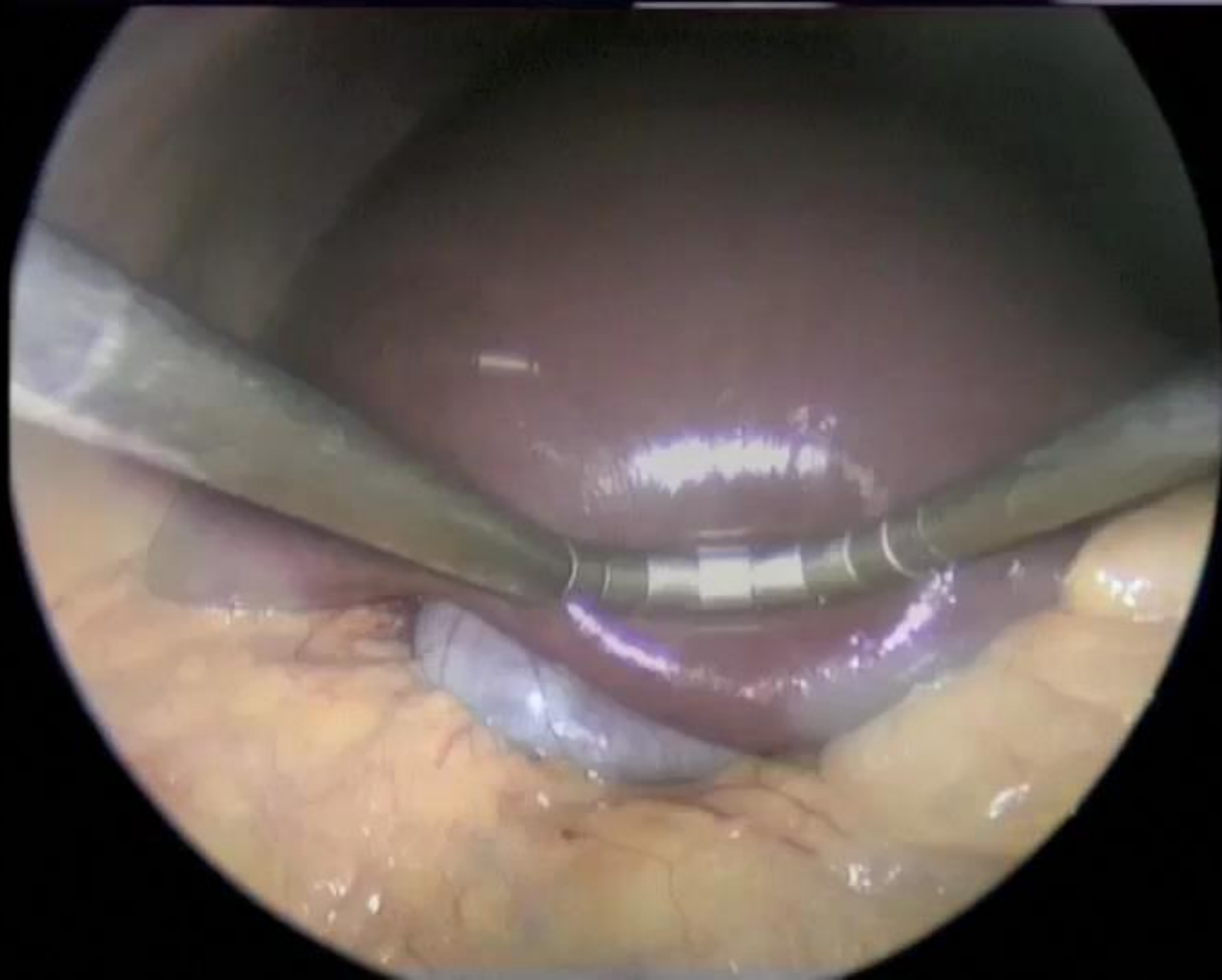

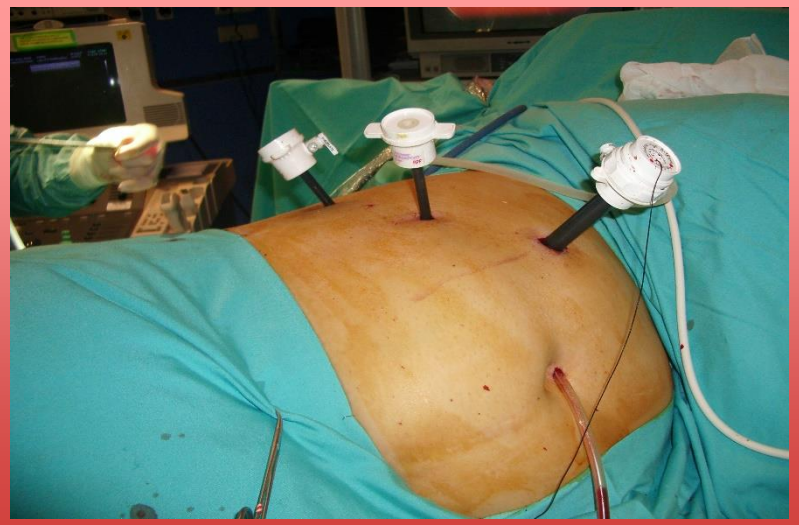

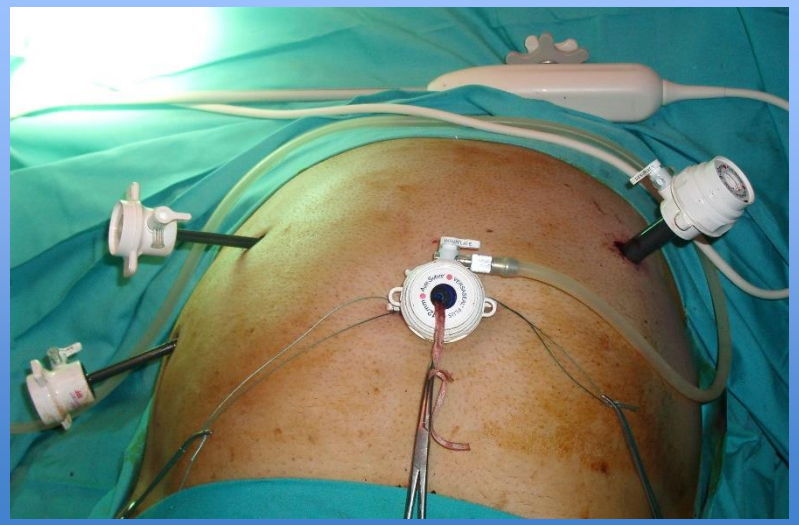

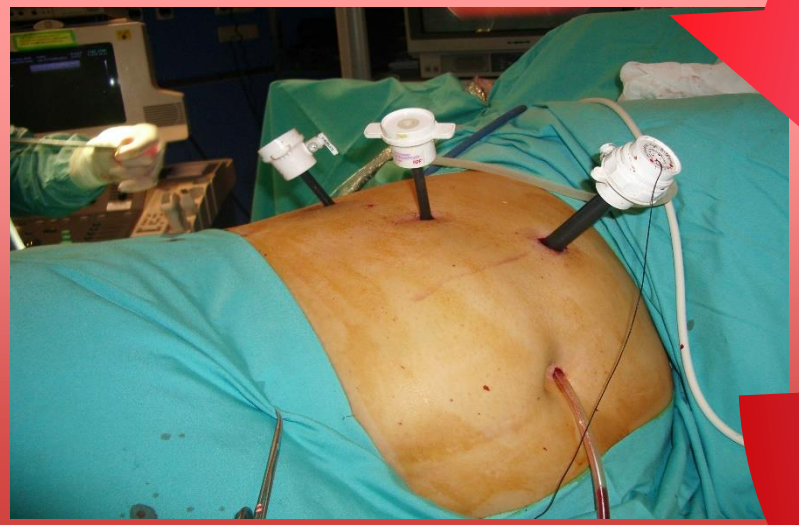

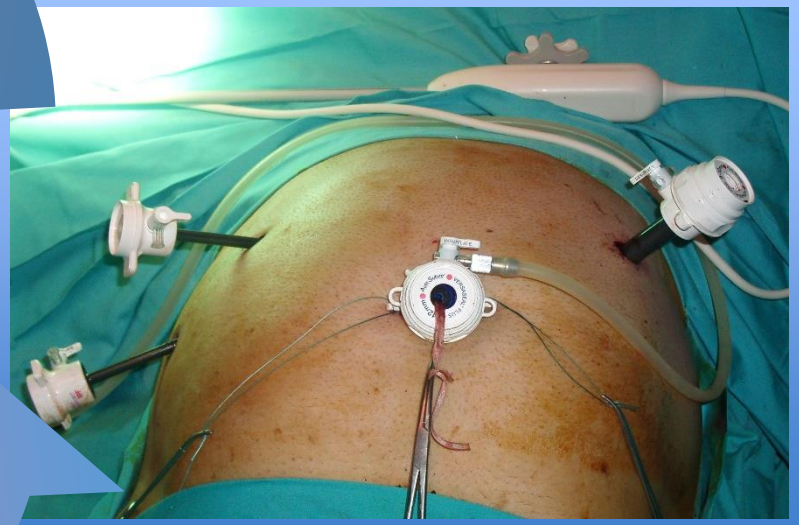

Liver mobilization and liver hanging for totally laparoscopic right hepatectomy: an easy way to do it

Fernando Rotellar [1,2] · Fernando Pardo [1,2] · Pablo Martí-Cruchaga [1,2] · Gabriel Zozaya [1,2] · Victor Valentí [1,2] · Manuel Bellver [1,2] · Luis Lopez-Olaondo [1,3] · Francisco Hidalgo [1,3]

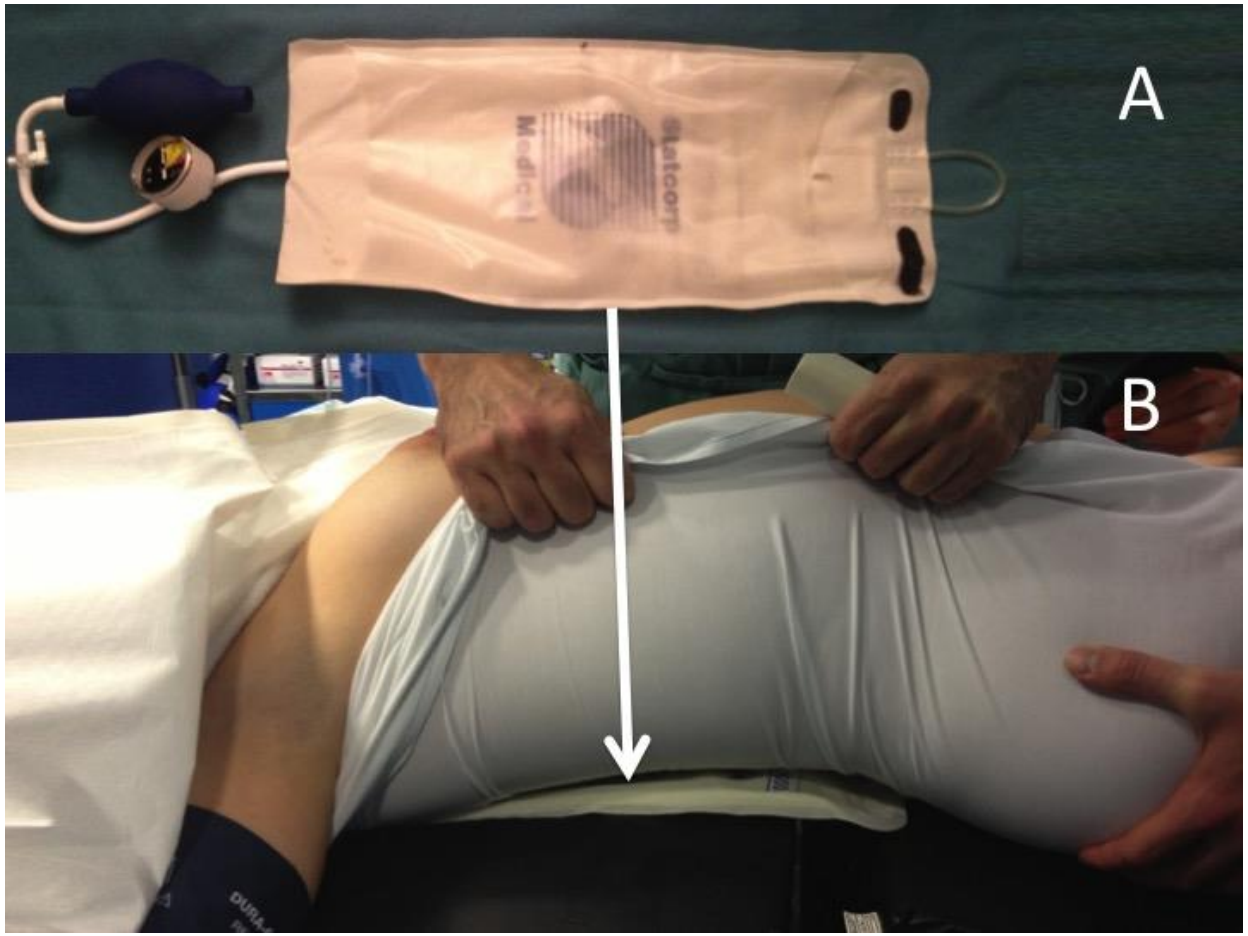

Langenbecks Arch Surg, 2016.

Liver mobilization and liver hanging for totally laparoscopic right hepatectomy: an easy way to do it

Fernando Rotellar [1,2] · Fernando Pardo [1,2] · Pablo Martí-Cruchaga [1,2] · Gabriel Zozaya [1,2] · Victor Valentí [1,2] · Manuel Bellver [1,2] · Luis Lopez-Olaondo [1,3] · Francisco Hidalgo [1,3]

A: flat position



B: left tilt

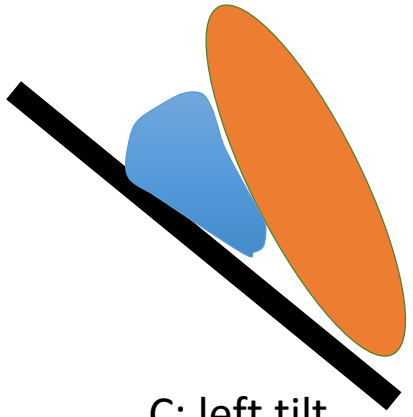

C: left tilt
+ balloon inflation

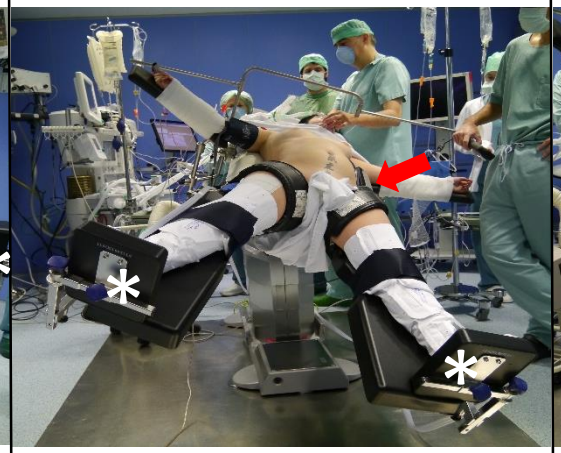

Langenbecks Arch Surg, 2016.

KARL STO

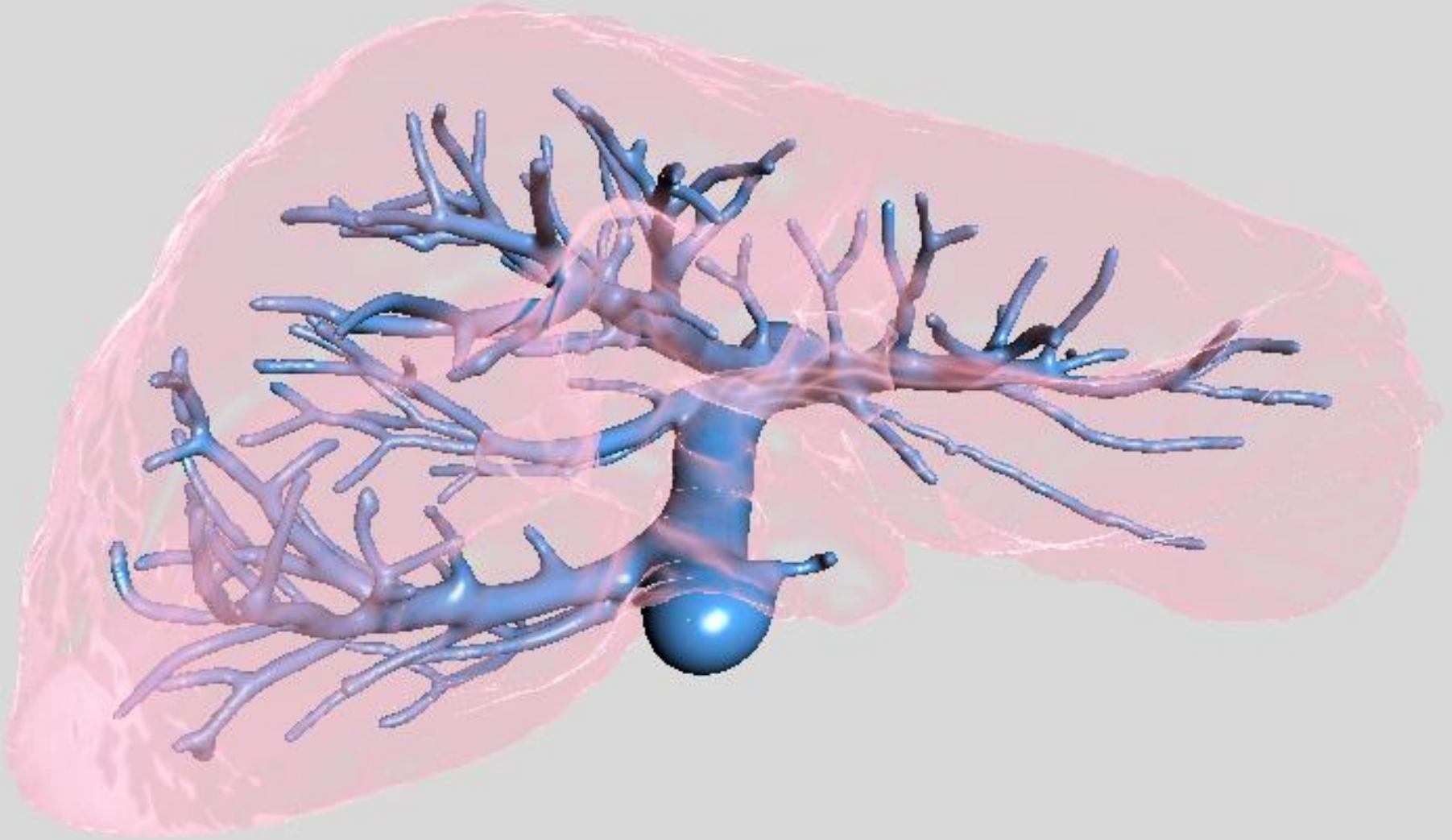

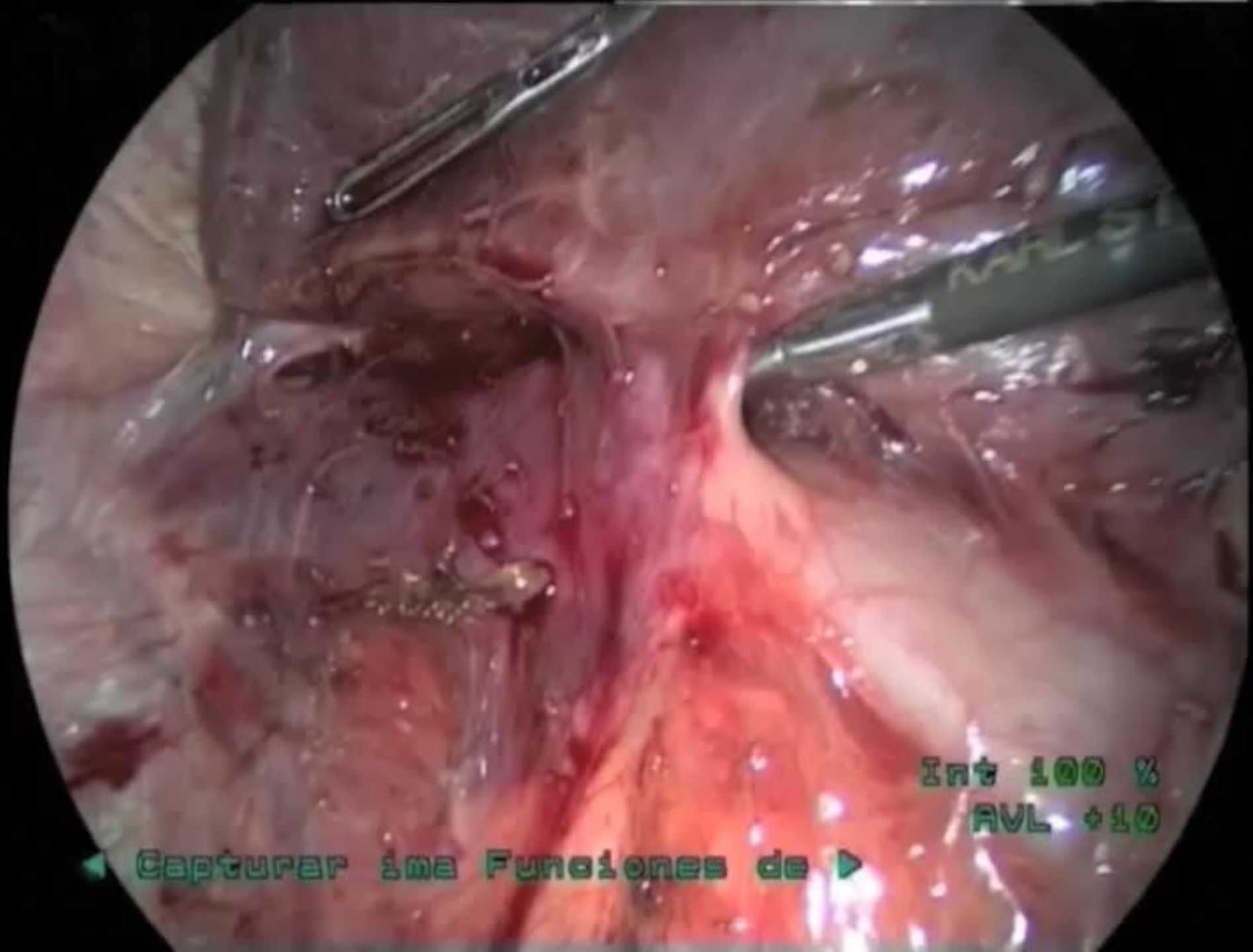
Int 100 %
AVL +10
Capturar ima Funciones de

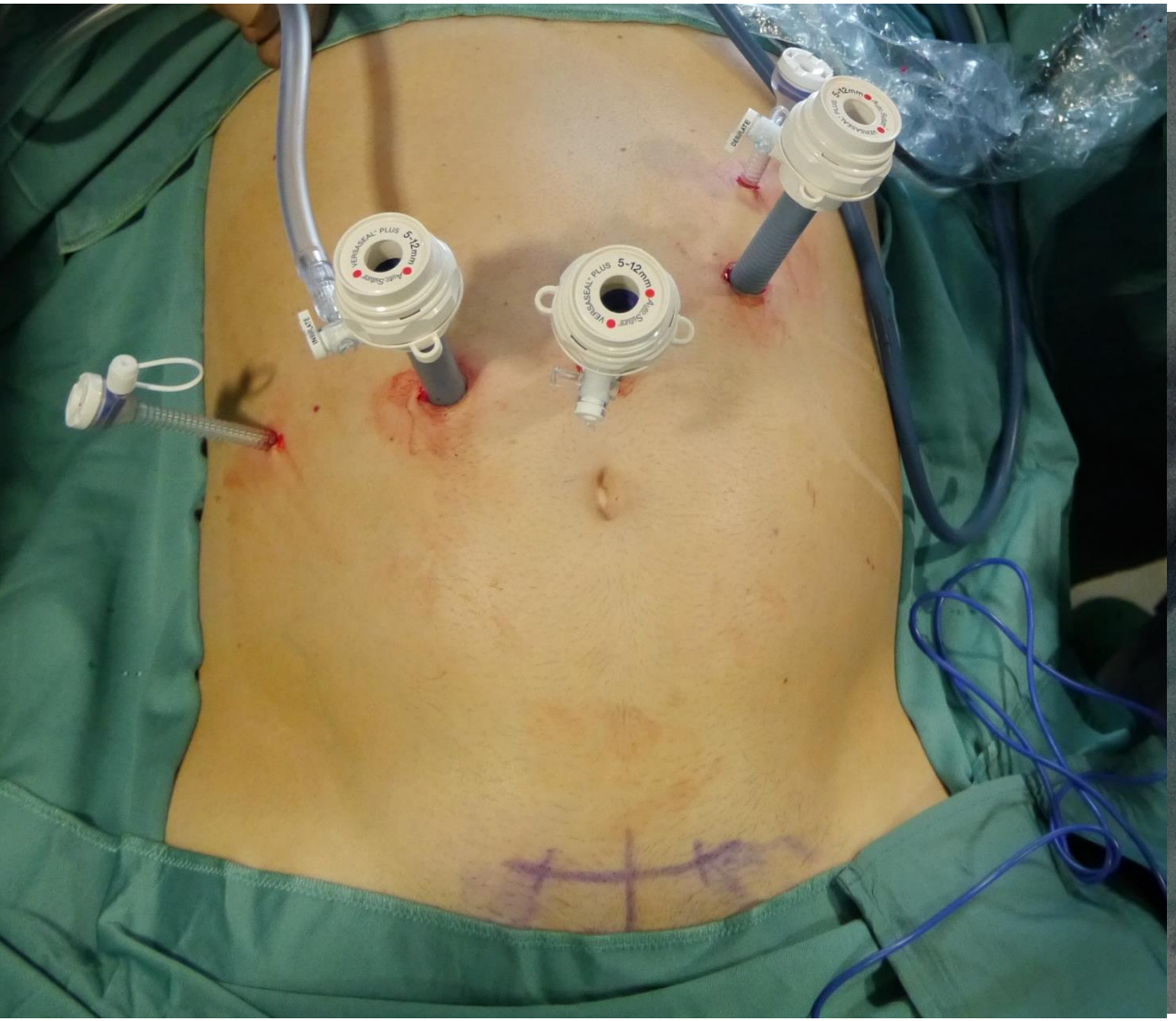
VERSASEAL PLUS 5-12mm
Auto Safety
VERSASEAL PLUS 5-12mm
Auto Safety
DEBILITE

KARL STO

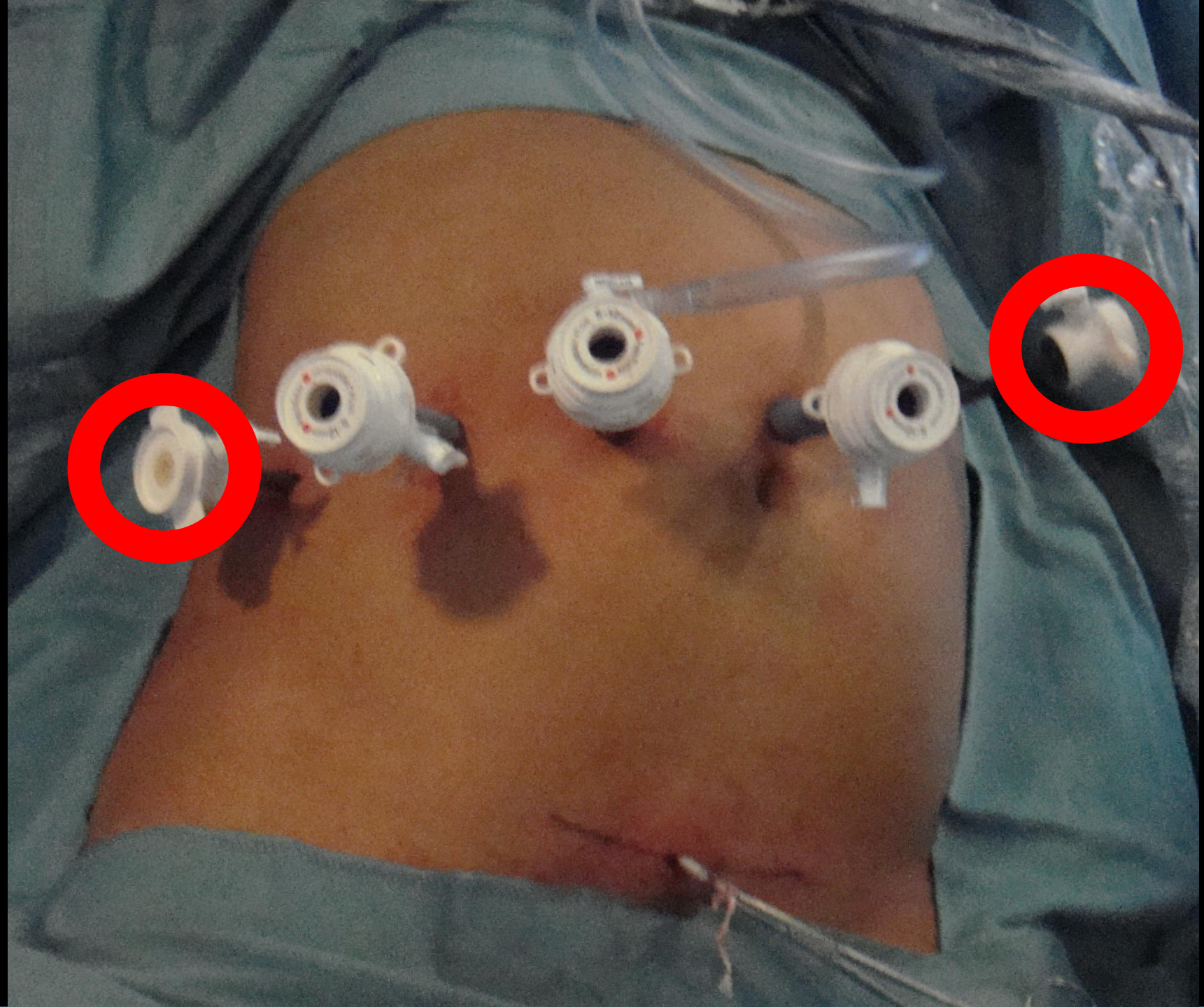

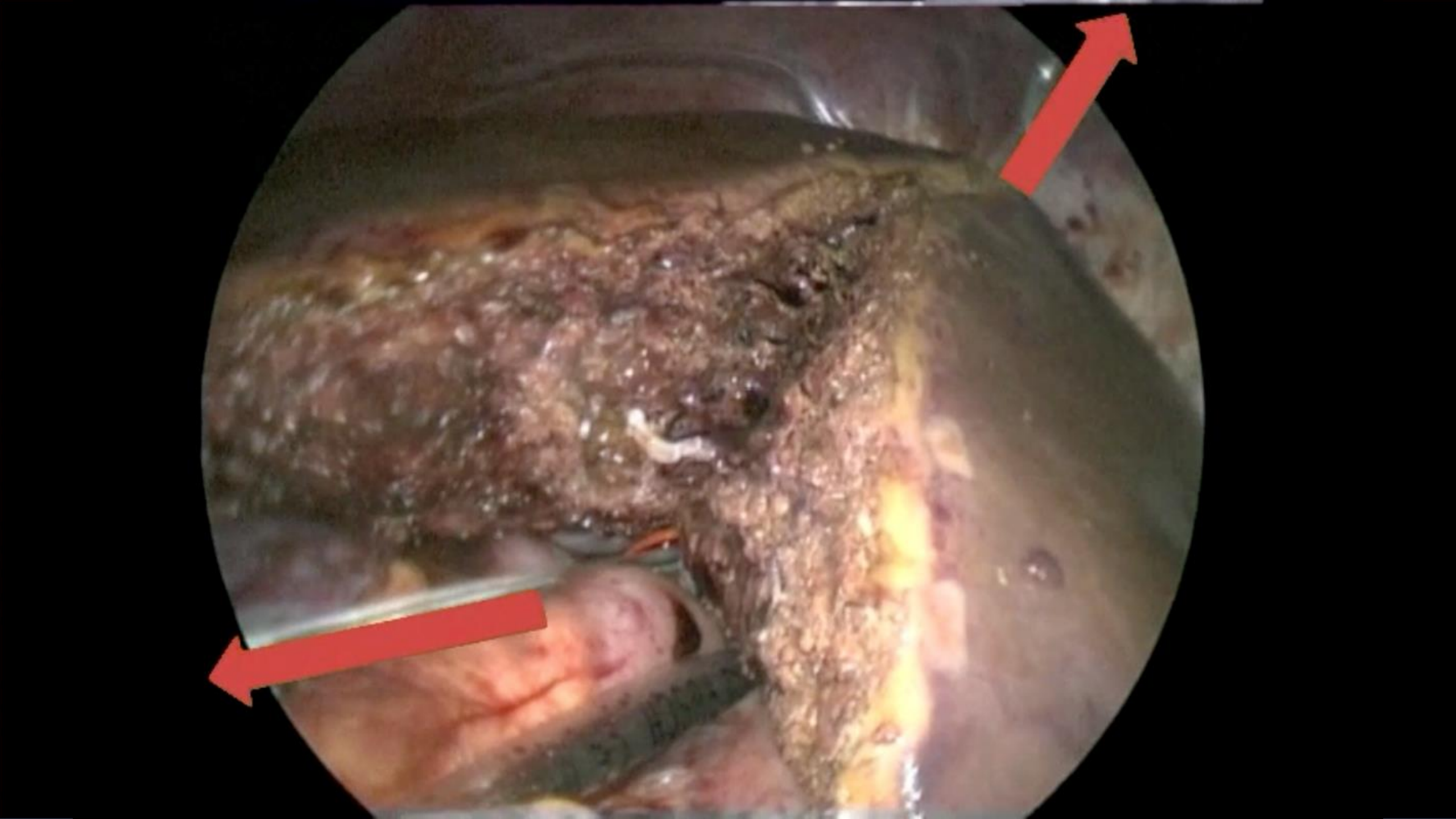

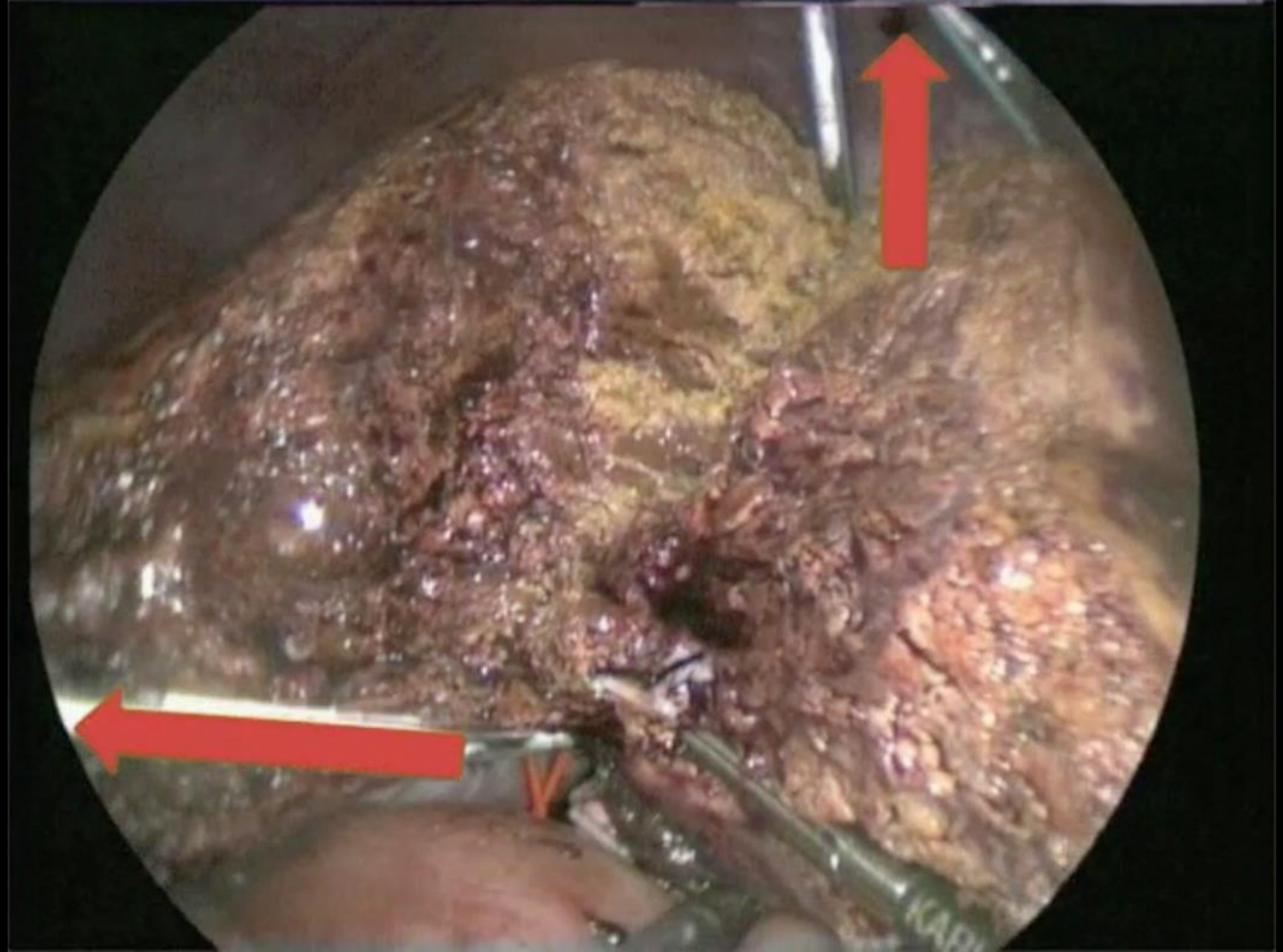

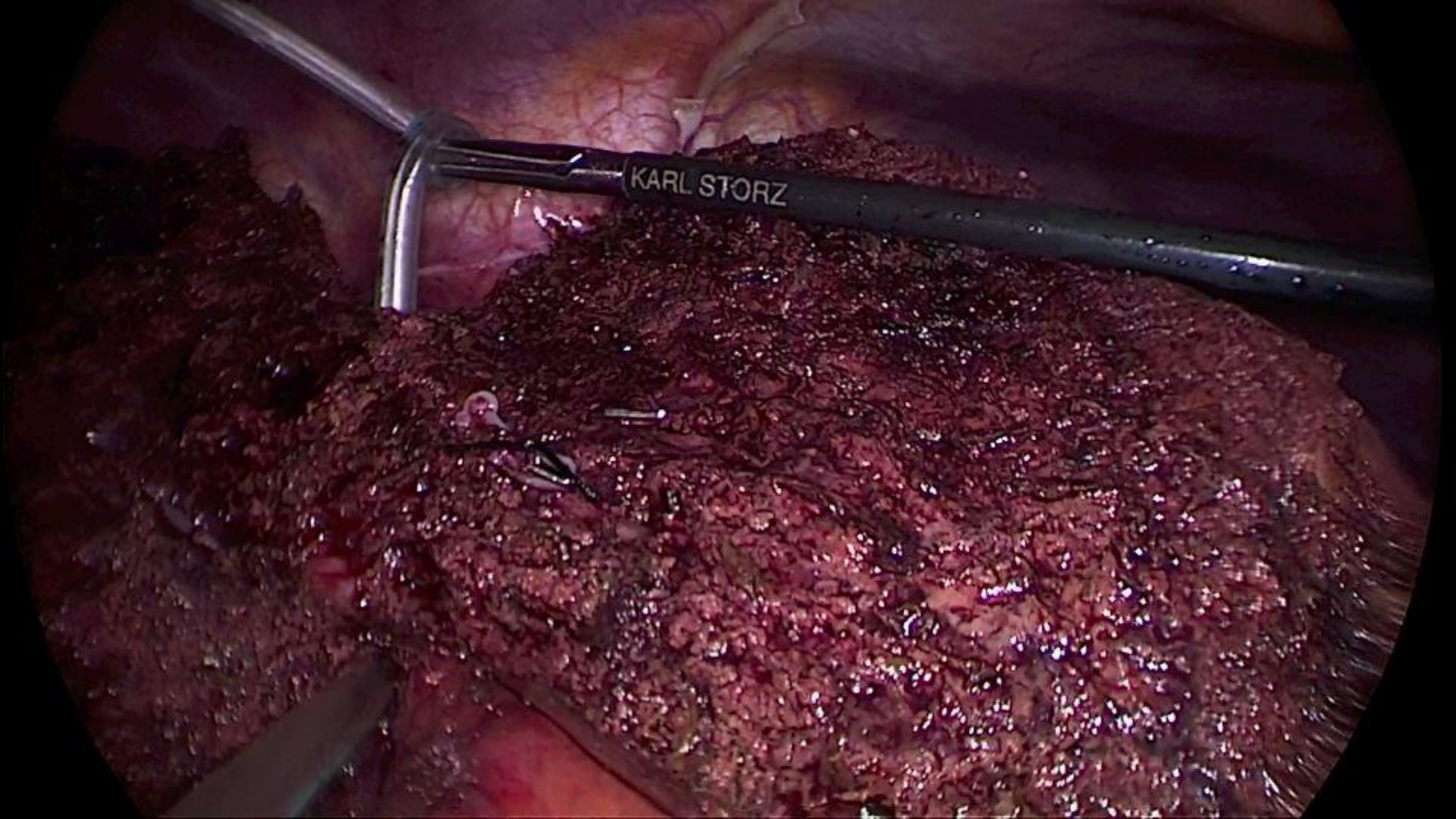
KARL STORZ

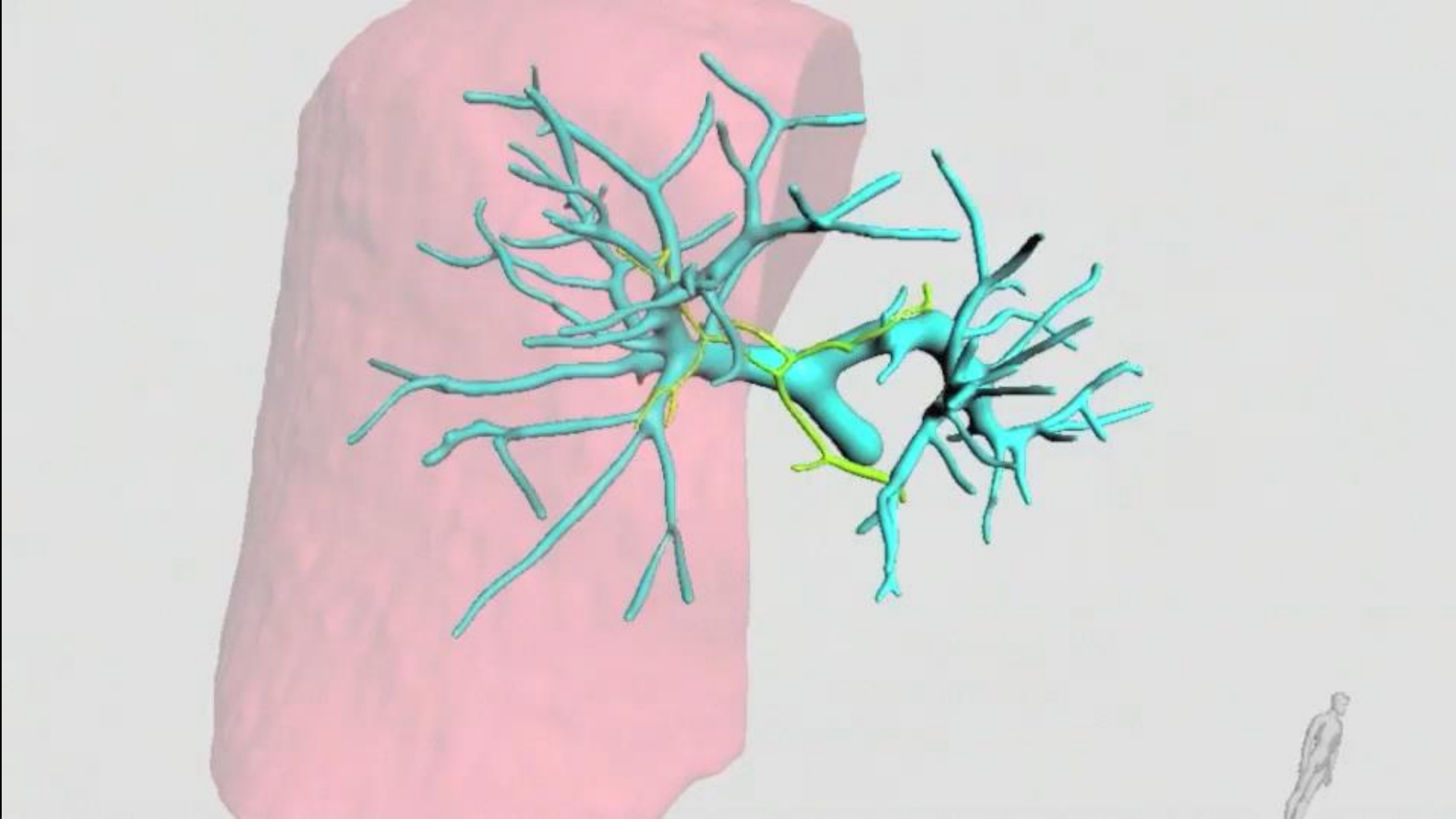

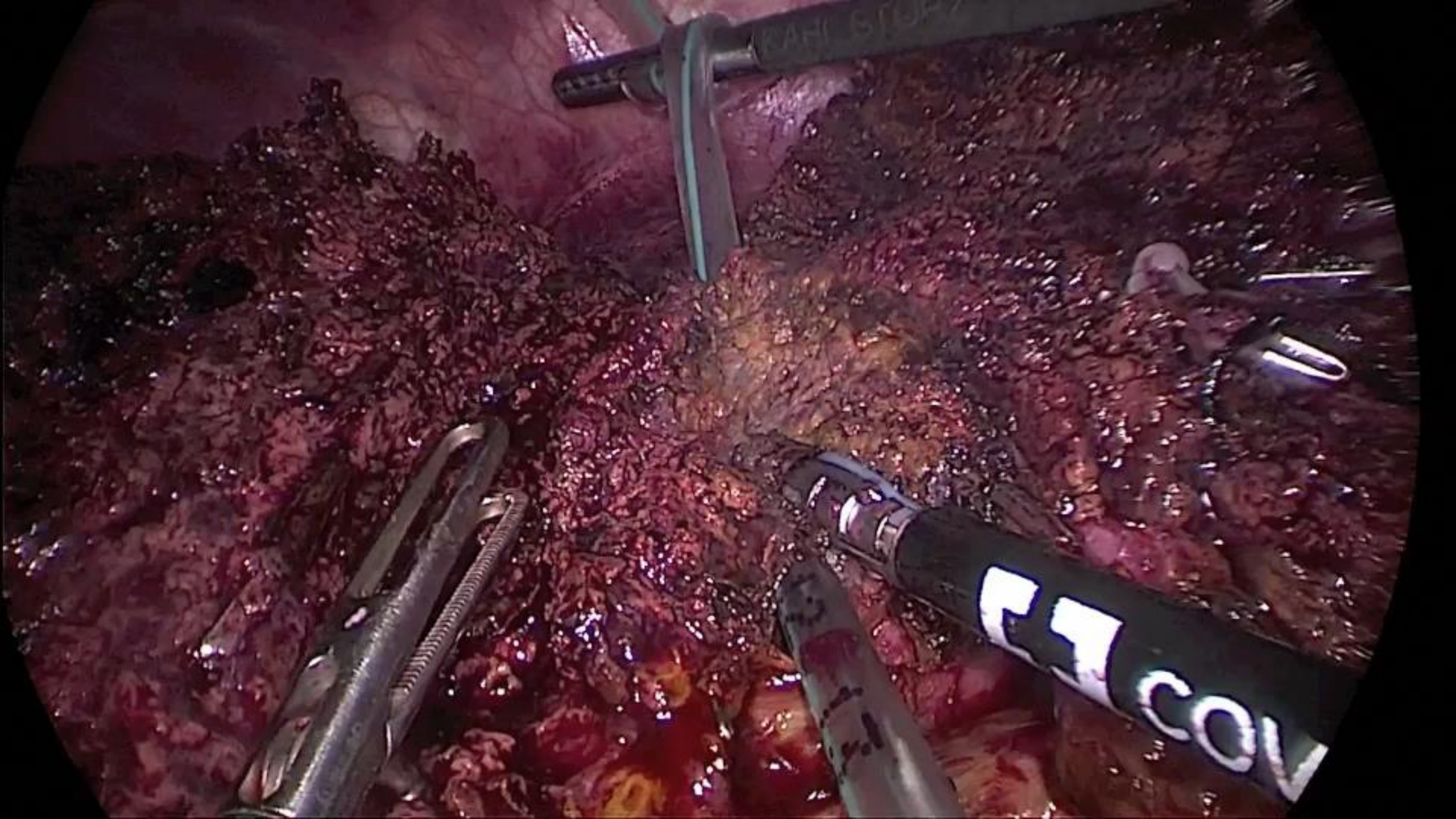

Preliminary experience and technical evolution on pure laparoscopic hepatectomy for adult LDLT

Clinica Universidad de Navarra, Pamplona, Spain

	Age/gender	Time (min)	Conversion	Pringle (min)	Blood loss
1	29/M	480	No	75	<100 ml
2	27/F	450	No	60	<200 ml
3	48/M	480	No	48	<100 ml
4	21/M	420	No	15	<100 ml
5	51/M	476	No	15	<100 ml
6	56/M	490	No	15	<100 ml
7	37/F	489	No	15	<150 ml

- Right
- Left

Preliminary experience and technical evolution on pure laparoscopic hepatectomy for adult LDLT

Clinica Universidad de Navarra, Pamplona, Spain

	Weight g.	Remnant (%)	Stay	Morbitity	INR (max)	Bb (max)	ALT (max)
1	879	39	4	Feverish	1.4	3,8	668
2	780	42	4	Gastroenteritis	1.5	1,06	252
3	767	36	5	No	1.8	1,86	343
4	1090	32	5	No	1.8	5,1	178
5	706	34	3	No	1.7	2,0	329
6	273	67	2	No	1.3	1,1	146
7	559	35	14	Cutaneous Rash Anxious/depressive Sd.	2.2	1,03	207

- Right
- Left

Preliminary experience and technical evolution on pure laparoscopic hepatectomy for adult LDLT

- This experience suggests that laparoscopic approach for LDLT hepatectomy is feasible and safe
- providing donors with the known benefits of the minimally invasive surgery
- Discussed technical aspects are simple modifications that faciltate and add safety to the procedure

Thank you

NAVARRENSIS · VNIVERSITAS · STVDIORVM ·
Clínica
Universidad
de Navarra